

# Influence of Moringa Leaf Meal As a Feed Additive on Antibody and Bursa Histomorphometry of Hybrid Ducklings

Febriana W<sup>1</sup>, Suprihatin T<sup>2</sup>, Kasiyati<sup>2\*</sup>

<sup>1</sup>Postgraduate Student, Department of Biology, Faculty of Science and Mathematics, Diponegoro University

Jl. Prof. H. Soedarto, SH, Tembalang, Semarang 50275, Central Java, Indonesia

<sup>2</sup>Department of Biology, Faculty of Science and Mathematics, Diponegoro University

Jl. Prof. H. Soedarto, SH, Tembalang, Semarang 50275, Central Java, Indonesia

E-mail: atikbudi77@gmail.com

(received 15-11-2022; revised 15-07-2023; accepted 24-07-2023)

## ABSTRAK

Febriana W, Suprihatin T, Kasiyati. 2023. Pengaruh tepung daun kelor sebagai pakan aditif terhadap antibodi dan histomorfometri bursa anak itik hibrida. JITV 28(4):251-258. DOI: <http://dx.doi.org/jitv.v28i4.3153>.

Tepung daun kelor mengandung berbagai fitonutrien yang bermanfaat bagi kesehatan hewan dan manusia. Penelitian ini dirancang untuk mengevaluasi tepung daun kelor sebagai pakan aditif terhadap respons antibodi dan histomorfometri bursa Fabricius itik hibrida yang diberi vaksin ND. Penelitian menggunakan rancangan acak lengkap, dengan total tiga puluh dua itik jantan hibrida berumur tiga hari yang dibagi menjadi empat kelompok perlakuan, dan masing-masing perlakuan terdiri atas delapan ulangan. Kelompok pertama diberi pakan standar komersial tanpa penambahan tepung daun kelor (0%), sedangkan kelompok kedua sampai keempat diberi pakan komersial standar dengan penambahan tepung daun kelor 2,5%, 5%, dan 7,5%. Semua kelompok mendapatkan vaksin ND1 dan ND2, masing-masing pada hari ke-tujuh dan ke-empat belas. Hasil penelitian menunjukkan bahwa pakan aditif tepung daun kelor berpengaruh tidak nyata pada titer antibodi, jumlah leukosit, limfosit (L), heterofil (H), rasio H:L, berat bursa, korteks, dan ketebalan medula bursa. Konsentrasi MDA serum, diameter plika, dan folikel bursa dipengaruhi ( $P < 0,05$ ) oleh aditif tepung daun kelor. Kesimpulan, pakan aditif tepung daun kelor dapat merangsang proliferasi folikel bursa dan tidak memiliki dampak buruk pada respons imun itik hibrida pascavaksin ND.

**Kata Kunci:** Tepung Daun Kelor, Itik Jantan, Titer Antibodi, Bursa Fabricius

## ABSTRACT

Febriana W, Suprihatin T, Kasiyati. 2023. Influence of moringa leaf meal as feed additive on antibody and bursa histomorphometry of hybrid ducklings. JITV 28(4):251-258. DOI: <http://dx.doi.org/jitv.v28i4.3153>.

Moringa leaf meal contains various phytonutrients that benefit animal and human health. This research is designed to evaluate Moringa leaf meal as a feed additive on antibody response and histomorphometry of the bursa Fabricius of hybrid duck administrated by ND vaccine. The experimental design used is a Completely Randomized Design (CRD) using thirty-two male hybrid ducks of three days old. They were divided into four treatment groups and eight replicates of each. The first group was standard commercial fed without adding of Moringa leaf meal (0%), while the second until the fourth group was a standard commercial fed with 2.5%, 5%, and 7.5% adding of Moringa leaf meal. All groups were vaccinated by ND1 and ND2, respectively, at the age of seventh and fourteenth days. The results showed that Moringa leaf meal as a feed additive had no significant effect on antibody titer, leukocyte count, lymphocytes (L), heterophils (H), H:L ratio, bursa weight, cortex, and medulla thickness of bursa. The concentration of serum MDA, the diameter of plica, and follicles bursa were significantly influenced ( $P < 0,05$ ) by adding Moringa leaf meal. In conclusion, the Moringa leaf meal additive could stimulate the proliferation of bursa follicles and have no adverse effect on the immune response of hybrid ducks post-ND vaccine.

**Key Words:** Moringa Leaf Meal, Male Ducklings, Antibody Titer, Bursa Fabricius

## INTRODUCTION

Hybrid ducks result from crossing two superior breeds that inherit a combination of dominant traits from both parents. Furthermore, hybrid ducks were developed to satisfy the need for breed ducks to produce high eggs or fast growth (Agriflo 2012). According to some research, ducks have a relatively good immune system, but it does not mean they cannot be exposed to bacteria, viruses, and fungi, which cause

infection or disease. Health management is crucial to avoid spreading disease in the environment (Hofmann et al. 2020). The immune system comprises several components, including leukocytes, detoxification organs, antibody-forming (liver and spleen), and immunomodulatory organs (thymus and Fabricius bursa). The Fabricius bursa is a place to produce B lymphocytes that benefit the humoral response, generating antibodies and differentiating immunoglobulin genes (Sulistiyanto et al. 2019).

Newcastle disease (ND) is well-known as Tetelo in Indonesia. It is an endemic disease in Indonesia, attacking respiratory and systemic, acute, and easily contagious. It is caused by the ND virus, which belongs to the Avian Paramyxovirus genus (Tabbu 2000; Widyaningsih et al. 2020). The pathogenicity of the ND virus varies depending on the host, and birds are susceptible to the ND virus (Tabbu 2000). However, Rozi et al. (2020) stated that cases of ND in chicken or duck farms have a morbidity and mortality rate close to 100% in unvaccinated poultry. Furthermore, Miller et al. (2010) showed that infected ducks do not show clinical or only mild clinical symptoms, even though the same ND virus strain was fatal to chickens. Meanwhile, there is currently no drug to cure it. Prevention is essential through vaccination and improved management of poultry rearing.

Vaccination is an effective way to protect and prevent poultry at various age levels from ND disease (Pratama et al. 2016; Yuliani & Sakan 2018). Unfortunately, the fact shows that the disease still happens in routinely vaccinated poultries (Widyaningsih et al., 2020). It raises the suspicion of the difference between the ND virus circulating in their life and the ND virus in the vaccine (Wibowo et al. 2013). An analysis showed genetic differences between the two ND viruses, giving rise to differences in antigenic responses (Xiao et al. 2012). In addition, low antibody titers cannot protect birds from the virus. Therefore, efforts have been made to increase antibody titers in poultry, which are expected to escalate their immune system. Natural ingredients such as phytonutrient components can help to modulate the immune system by repairing imbalances in the body's defense system, increasing antibody production, cellular immune responses, and the phagocytic ability of macrophages (Amir et al. 2014).

The leaves of the *Moringa oleifera* contain complete nutrients and various phytochemical components for health benefits. It has the main polyphenolic constituents, namely flavonoids in the form of kaempferol, myricetin, quercetin, and phenolic acids such as gallic acid. The flavonoids have a role in hypoglycemic, antibacterial, antifungal, antioxidant, and anti-inflammatory (Fidrianny et al. 2021). Phytochemicals in Moringa leaf, especially polysaccharides, also have potential as immunostimulants and immunomodulators (Li et al. 2020). Dillasamola et al. (2018) also stated that the leaf extract could increase the number of leukocytes. Meanwhile, Soha et al. (2020) found that supplementing the Moringa in broiler food could reduce degenerative changes by regulating mRNA presentation. It could modulate immune responses.

The use of Moringa leaf meal as a feed additive is still being explored today. Feed additives are bioactive compounds intentionally added to the ration in small

amounts (Righi et al. 2021). There are many studies about Moringa leaf meal as a feed additive to increase animal production. However, the research on it as the immune response of ND-vaccinated is still much limited. This research is designed to evaluate the effect of Moringa leaf meal as a feed additive on antibody response and histomorphometry of the bursa Fabricius of male hybrid ducklings.

## MATERIALS AND METHODS

### Experimental animal, raising management, and research design

All experimental animals used in this study were raised following the protocol determined by the Department of Biology, and it has been approved by the Health Research Ethics Commission, Faculty of Medicine Diponegoro University, No. 04/EC/H/FK/-UNDIP/I/2022. The male hybrid ducklings used in this study were a crossbreed of Peking and Magelang ducks. There were 32 ducks, three days old, obtained from hybrid duck breeders in Karangjati, Semarang Central Java, Indonesia. Hybrid ducks had been acclimatized for one week in a box cage and moved into a battery cage sizing of 45×35×65 cm<sup>3</sup>. Food and drink were accessible *ad libitum*. The feeding time was two times a day in the morning (07:00 am) and afternoon (03:00 pm). Temperature and humidity are monitored every day.

This study used a completely randomized design with four different concentrations of Moringa leaf meal, *i.e.*, 0% or standard commercial feed without Moringa leaf meal and standard commercial feed with the addition of 2.5%, 5%, and 7.5% Moringa leaf meal. Each treatment consisted of eight replications. The addition of dietary Moringa leaf meal was administered for six weeks.

### Feed preparation

The food was a common feed used by breeders, standard commercial feed BR1 for ducks aged 1-3 weeks and standard commercial feed BR2 for those aged 4-8 weeks. The feedstock was made once a week. Meanwhile, the Moringa leaf meal was collected from the local market produced by Flozindo Purbalingga, Central Java Indonesia. BR1 or BR2 was mixed with the Moringa meal homogeneously. The composition of the feed ingredients is presented in Table 1.

### Analysis of antioxidant, vitamin D, and vitamin E of Moringa leaf meal

Analysis of antioxidants used the DPPH method. The absorbance value was then measured using a UV-

**Table 1.** Feed composition and nutrient content of addition of Moringa leaf meal treatments of male hybrid ducklings

Feed Ingredient	Moringa leaf meal concentration in feed (%)							
	Starter Period (1-3 weeks)				Finisher Period (4-8 weeks)			
	0	2.5	5	7.5	0	2.5	5	7.5
Standard commercial feed, (%) <sup>1)</sup>	100	97.5	95	92.5	100	97.5	95	92.5
Moringa leaf meal, (%)	0	2.5	5	7.5	0	2.5	5	7.5
Total, (%)	100	100	100	100	100	100	100	100
Nutrient content								
Metabolic energy (kcal/kg)	2970.20	2947.14	2924.08	2901.01	3040	3016.94	3000.88	2949.81
Crude protein, (%)	21.94	22.29	22.64	22.99	18.63	18.98	19.31	19.74
Crude fat, (%)	3.55	3.49	3.42	3.35	7.26	7.19	7.11	7.07
Crude fiber, (%)	3.56	3.52	3.47	3.43	4.26	4.22	4.12	4.00
Calcium, (%)	0.78	0.79	0.79	0.80	0.87	0.87	0.88	0.88
Phosphor, (%)	0.51	0.50	0.48	0.47	0.50	0.49	0.47	0.47

The standard commercial feed in this study contains yellow corn, rice bran, meat bone meal (MBM), crude palm oil (CPO), pollard, corn gluten meal (CGM), vitamins, and minerals.

Vis spectrophotometer at a wavelength of 517 nm to determine the IC50 (Susanty et al. 2019). Furthermore, analysis of the content of vitamins E and D used the HPLC method with a normal phase. The detector was a UV detector (Widada 2013).

**ND (Newcastle Disease) vaccine and antibody titer measurement**

This study used the Medivac ND La Sota vaccine for ducks aged 7 and 14 days. Both types of vaccines were administered to ducks through the eye (ocular route) according to the protocol listed by the vaccine manufacturer. Moreover, blood samples for antibody titer measurements were taken at week 0 (pre-vaccine), 1, 2, 3, and 4 post-vaccine.

Blood samples were taken from the cranial tibial vein using a 1 ml syringe. Then, blood was transferred into a non-EDTA tube to produce serum. The collected serum was stored in an Eppendorf tube at -20°C until the antibody titer was measured using the Haemagglutination Inhibition (HI) test (Novitasari et al. 2018).

**Measures of leukocytes, blood MDA, and histomorphometry of Fabricius bursa**

Blood sampling for calculating the leukocyte number and its differential was carried out at week 8. It was taken through the brachial vein using a 3 ml

syringe. Half of the blood was collected in the EDTA tube, and the rest was in non-EDTA. All blood samples in the EDTA tube were subjected to calculating the leukocyte and its differential through a hematology analyzer in the laboratory. Meanwhile, blood in a non-EDTA tube was prepared for counting the MDA (malondialdehyde) level. The TBA method was then used to measure the level of MDA (Maggi-Capeyron et al. 2002).

The organ for histomorphometry incision was the Fabricius bursa. It was obtained after the ducks were sacrificed by the halal method, by cutting the jugular, oesophageal, and tracheal veins and arteries. The bursa of Fabricius was isolated and then weighed to calculate the ratio of bursa weight to body weight (bursa weight/body weight x 1000). Furthermore, the bursa was fixed into 10% BNF (neutral formalin buffer), and histological preparations were made by paraffin method and hematoxylin-eosin (HE) staining. The histological preparations were then observed using a photomicrograph to obtain a histomorphology of the Fabricius bursa. Furthermore, measurements of plica diameter, number of follicles per plica, follicle diameter, medullary thickness, and cortex thickness of bursa were measured.

**Data analysis**

The data was analyzed using one-way ANOVA at a significance level of 5%. A further test was using the

Least Significant Difference (LSD). All data analyzed were calculated by SPSS 24 software.

## RESULTS AND DISCUSSION

### Antibody response

The results of antibody titer analysis in hybrid ducks after the administration of ND1 and ND2 vaccines, followed by the addition of Moringa leaf meal in feed, did not show a significant effect in the first week until the fourth-week post-vaccine (Table 2). At week 0 (pre-vaccine), antibody titers also showed no significant difference. The antibody titer measurement using the HI test was positive if the antibody titer was  $2^4$  (OIE 2021).

Examining the pre-vaccine antibody titers (week 0 or ducks aged six days) aimed to measure the maternal antibodies. The results (Table 2) showed that hybrid ducks' circulation systems still had maternal antibodies. They derived from transferred parental blood deposited into the yolk to protect the ducklings on the first day post-hatching. Not only that, but they also affect the health of the ducklings because of the gamma globulins inherited from parents through passive immune transfer to protect ducklings from viruses and microorganisms. The average antibody titer of hybrid ducks in this study is equal to the results of the Bali duck antibody titer examination conducted by Novitasari et al. (2018). Windi et al. (2016) stated that maternal antibodies will decrease along with the duckling age.

The antibody titers in the first-week post-ND1 vaccine of all treatment groups showed almost the same mean and had no significant changes. According to criteria from OIE (2021), the mean antibody titer of all measured samples was seronegative because it was less than  $2^4$ . Pratama et al. (2016) stated that passively obtained maternal antibodies could inhibit the formation of immunoglobulins, thus affecting the vaccine. If they are still in the circulating system, the first vaccination

should not be too early because these antibodies will neutralize the vaccine antigens.

Measurements at 2 to 4 weeks after booster vaccine (ND2) also showed no significant increase in antibody titer. Generally, antibodies would increase after three weeks or more post-vaccination using an active vaccine. Vaccination in hybrid ducks aged 7 and 14 days in this study was not effective because there was still the influence of maternal antibodies. Pratama et al. (2016) stated maternal antibodies would run out in 10-20 days post-hatching. They effectively prevented the success of vaccination. Kurnianto et al. (2016) and Novitasari et al. (2018) said that the active vaccine, which contains a live attenuated virus, could change the protective antibodies of chickens within three weeks of a booster vaccination. Furthermore, Bhakty et al. (2018) suggested that differences in the immune response level of hybrid ducks could come from several factors, including differences in individual responses and the antigenic ability of the vaccine antigens.

On the other hand, the low total antibody titers post-vaccine ND1 and ND2 in this research might be related to the phytonutrient content in the Moringa leaf meal. The phytonutrients used as feed additives can also affect the vaccine's success. Protein, vitamin D, vitamin E, and carotenoids are phytonutrients in Moringa leaf meal that tend to be immunomodulators. Administration of both vaccines and exposure to pathogens will enhance the acute phase response. The need for nutrients in the liver increases due to the acute-phase protein synthesis. Then, these proteins are distributed throughout the body to protect the epithelial surface and provide epithelial stability. Vitamin D, vitamin E, and carotenoids also play roles as antioxidants. These antioxidants could protect cells that synthesize acute-phase proteins. Moringa leaf meal in this study contained 15.161 mg/L of vitamin E and 7.160 mg/L of vitamin D. In addition, its antioxidant activity has an  $IC_{50}$  value of 1.289 mg/mL or equivalent to 1.289 ppm. The value of antioxidant activity in Moringa leaf meal was shallow but still has the potential as an antioxidant. Phongpaichit et al. (2007)

**Table 2.** Average antibody titers of hybrid ducklings pre-vaccine (week 0) and post-vaccine ND1 and ND2 (week 1 to 4) followed by feeding the addition of Moringa leaf meal

Sampling week	Moringa leaf meal concentration (%)			
	0	2.5	5	7.5
0	$2^{0.75} \pm 0.18$	$2^{0.88} \pm 0.12$	$2^{1.00} \pm 0.10$	$2^{0.88} \pm 0.20$
1*	$2^{1.31} \pm 0.24$	$2^{1.29} \pm 0.13$	$2^{1.23} \pm 0.26$	$2^{1.25} \pm 0.17$
2*	$0.00 \pm 0.00$	$0.00 \pm 0.00$	$0.00 \pm 0.00$	$0.00 \pm 0.00$
3	$0.00 \pm 0.00$	$0.00 \pm 0.00$	$0.00 \pm 0.00$	$0.00 \pm 0.00$
4	$0.00 \pm 0.00$	$0.00 \pm 0.00$	$0.00 \pm 0.00$	$0.00 \pm 0.00$

\*Time of vaccines: There was no significant difference between all treatments. The data are shown as average  $\pm$ SD

stated that the smaller the IC50 value, the higher the antioxidant activity was. Furthermore, Saputra et al. (2020) showed that all antioxidant phytochemical compounds in Moringa leaf meal had functions to neutralize free radicals, protect against oxidative damage, significantly inhibit cell aging, and protect cells from oxidative stress. Okoroafor et al. (2021) proved that vitamin E could enhance immune function against viral pathogens and modulate the function of T cells and cytokines.

### **Amount of leukocyte, blood MDA, and histomorphometry of bursa**

The results of leukocytes, heterophile (H) and lymphocyte (L) differentials, H:L ratio, and blood MDA in hybrid ducklings fed with Moringa leaf meal are presented in Table 3. The number of leukocytes, heterophils, lymphocytes, and H:L ratio (Table 3) showed no significant difference. The administration of vaccines and adding Moringa leaf meal fed to hybrid ducklings did not cause changes in the number of leukocytes and the differential number of leukocytes. The formation and performance of leukocytes were not affected by phytonutrient components in the Moringa leaf meal. However, the leukocyte count in this study was higher than the normal range. According to Saputro et al. (2016), the high number cannot assume the poultry is sick. It could be because the unbalanced nutrient content affected antibodies and leukocytes. Purnomo (2015) stated that the normal leukocyte in poultry ranges from  $6-40 \times 10^3/\text{ml}$ . Differences in the number of leukocytes, heterophils, lymphocytes, and the ratio of H:L between this study and previous studies may be related to the type of poultry, age, nutrition, treatment, and health status.

The leukocyte differentials (heterophile and lymphocyte) showed the same values for all groups (Table 3), as well as the H:L ratio. It means the hybrid ducklings in this study were at the same level of health, which is in line with Kasiyati et al. (2021), who explained that adding Moringa leaf meal did not cause many lymphocytes, heterophils, and eosinophils of Pengging ducks. The similarity in the ducks' health was because of the bioactive content in the Moringa leaf meal, which had a good impact on the ducks' health. Rahmayanti and Isroli (2019) stated that the antibacterial content of Moringa leaves could reduce parasites. Heterophiles are the front line against bacterial infections, and the number of heterophils will not be affected if there is no infection.

Blood MDA (*Malondyaldehyde*) levels (Table 3) showed significantly different ( $P < 0.05$ ). MDA levels decreased along with the increase in the concentration of Moringa leaf meal. The Moringa leaf meal in this study contains natural antioxidants such as beta-

carotene, vitamin D, and vitamin E. Natural antioxidants work rapidly to protect cell membranes from oxidative damage or prevent lipid peroxidation due to free radicals or reactive oxygen species (ROS). It could come from the normal processes of metabolism energy or exposure to pathogens. In general, the elimination of pathogens by macrophages or other components of the immune system can release toxic metabolites as weapons to kill pathogens or microorganisms. Side effects of the microbicidal activity of the immune system are host cell killing, cell and tissue injury, oxidative degradation, and production of ROS or free radicals. Overproduction of ROS can result in damage to various macromolecules, so it stimulates pathological conditions and disease. Antioxidants can protect cells from the harmful effects of cytotoxic free radicals or ROS. Free radical concentration could be approached by measuring the MDA. Sun et al. (2022) stated that adding vitamin E supplementation in poultry could significantly increase the activity of antioxidant enzymes and reduce the MDA content in the serum. Similarly, Sahin et al. (2003) reported that vitamin E supplementation also decreased serum and liver MDA concentrations of Japanese quail.

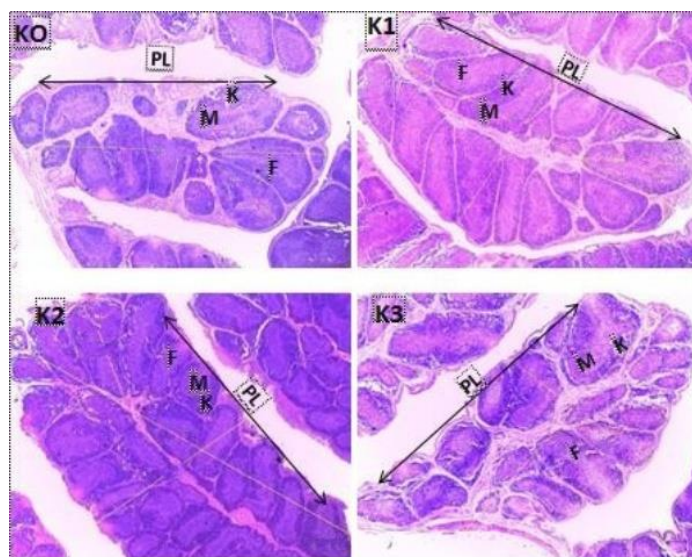
There was no change in the morphology of the bursa of Fabricius in hybrid ducklings that had been vaccinated and fed with Moringa leaf meal additive. Bursal weight, bursa: body weight ratio, follicle diameter, medullary thickness, and bursa cortex thickness were not significantly different (Table 3) in all treatment groups. However, the diameter of the plica and the number of follicles per plica in the bursa were significantly different ( $P < 0.05$ ; Table 3). Raji et al. (2017) stated that the size of the bursa was affected by stress conditions (due to temperature and disease), vaccines, mycotoxins, and rearing systems. The size of the bursa, which was relatively the same in all treatment groups, indicated that ND1 and ND2 vaccines and the addition of Moringa leaf meal in the diet did not increase the number of antibodies (Table 2), did not interfere with the development of the bursa, and did not cause hyperplasia or atrophy of the Fabricius bursa. The bursa weight and ratio of the bursa to body weight are indicators to assess the immune system. Apriliyani et al. (2013) suggested that bursa that often form antibodies can cause follicle depletion and shrinkage. It will affect the relative weight of the bursa.

The diameter of the plica and the number of follicles per plica in the bursa increased ( $P < 0.05$ ) in the 5% Moringa leaf meal group. The diameter of plica in a 5% group was the largest, with the highest number of follicles compared to the control group (0% Moringa leaf meal). The diameter and number of follicles increase in line with the age of the birds. Figure 1 showed that the hybrid ducklings group feeding Moringa leaf meal of 2.5% and 5% had many follicles

**Table 3.** Average leukogram, blood MDA, morphometry of the Fabricius bursa of hybrid ducklings post-vaccine ND1 and ND2 and followed by feeding the addition of Moringa leaf meal

Parameter	Moringa leaf meal concentration (%)			
	0	2.5	5	7.5
Leukocytes, ( $\times 10^3/\text{ml}$ )	157.4 $\pm$ 22.29	161.7 $\pm$ 25.99	149.3 $\pm$ 31.39	135.2 $\pm$ 22.37
Heterophile, ( $\times 10^3/\text{ml}$ )	3.01 $\pm$ 0.24	2.49 $\pm$ 1.01	2.83 $\pm$ 0.78	2.91 $\pm$ 0.35
Lymphocytes, ( $\times 10^3/\text{ml}$ )	148.8 $\pm$ 21.45	153.8 $\pm$ 25.81	141.3 $\pm$ 28.28	127.1 $\pm$ 21.15
H:L ratio	0.06 $\pm$ 0.01	0.04 $\pm$ 0.03	0.05 $\pm$ 0.03	0.06 $\pm$ 0.01
Blood MDA (nmol/ml)	2.35 <sup>a</sup> $\pm$ 0.18	1.99 <sup>b</sup> $\pm$ 0.09	1.75 <sup>c</sup> $\pm$ 0.09	1.39 <sup>d</sup> $\pm$ 0.11
Bursal Weight, (%)	0.76 $\pm$ 0.04	0.75 $\pm$ 0.02	0.78 $\pm$ 0.04	0.81 $\pm$ 0.05
Bursa: Body weight ratio	1.11 $\pm$ 0.27	1.07 $\pm$ 0.12	1.27 $\pm$ 0.21	1.43 $\pm$ 0.29
Diameter of plica, (mm)	2.13 $\pm$ 0.06 <sup>b</sup>	2.28 $\pm$ 0.12 <sup>b</sup>	2.75 $\pm$ 0.23 <sup>a</sup>	2.48 $\pm$ 0.36 <sup>ab</sup>
Number of follicles per plica	11.42 $\pm$ 1.75 <sup>b</sup>	20.49 $\pm$ 8.19 <sup>ab</sup>	31.87 $\pm$ 10.84 <sup>a</sup>	19.83 $\pm$ 0.56 <sup>ab</sup>
Follicle diameter (mm)	0.72 $\pm$ 0.09	0.66 $\pm$ 0.05	0.73 $\pm$ 0.09	0.74 $\pm$ 0.13
Medullary thickness (mm)	0.20 $\pm$ 0.05	0.18 $\pm$ 0.02	0.20 $\pm$ 0.03	0.22 $\pm$ 0.05
Cortex thickness (mm)	0.16 $\pm$ 0.01	0.15 $\pm$ 0.01	0.20 $\pm$ 0.04	0.19 $\pm$ 0.04

<sup>a-d</sup>= Numbers followed by different superscripts in the same row indicate significantly different ( $P < 0.05$ ); The data are shown as average  $\pm$  SD; MDA=Malondyaldehyde; H=Heterophile; L= Leukocytes



**Figure 1.** Bursa Fabricius hybrid ducklings with ND1-2 vaccine and Moringa leaf meal. KO (control), K1 (2.5% added Moringa leaf meal), K2 (5% Moringa leaf meal added), and K3 (7.5% Moringa leaf meal added). PL: Plica, F: Follicle, M: Medulla, K: Cortex. HE staining, 40 $\times$  magnification

with a tight arrangement, regular interfollicular septa, no space between follicles, and no signs of system damage. The increasing number of bursa follicles indicated that the research ducks could recognize the virus administration in the form of the ND vaccine. It successively stimulated bursa follicles to proliferate to compensate for the production of lymphocytes. The escalating number of follicles per plica contributes to raising the size of the plica's diameter.

Vaccination in poultry can affect the histomorphometry of the bursa. In general, there are three stages of vaccine exposure to the pathophysiology and histology of the bursa, namely 1) the acute inflammatory stage, characterized by the rising size of the bursa, occurring about four days post-virus infection (vaccine exposure), 2) the sub-acute stage, characterized by spontaneous regression of the bursa. Quickly, the bursa can return to its original size, and 3)

the final stage, characterized by atrophy of the bursa, an increase in the stock exchange index, and the ratio of stock exchange weight to body weight (Raji et al. 2017). Phytonutrient components of Moringa leaf meal were also indicated to be active in the proliferation of bursa follicles and maintaining follicle size. Phytonutrients, such as polyphenols, flavonoids, flavonols, and non-phenolic components (vitamins, proteins, oligosaccharides), are antioxidants to boost the immune system and poultry health.

### CONCLUSION

Adding 5% Moringa leaf meal in feed could optimally stimulate the proliferation of bursa follicles and improve the immune status of hybrid ducklings. This study can be applied, but it is necessary to evaluate the administration of the ND vaccine to increase the efficacy of the ND vaccine in ducks.

### ACKNOWLEDGEMENT

The author is very grateful to the staff of the Semarang type B Veterinary Laboratory for providing facilities to do histological observations. The Faculty of Science and Mathematics funded it with research contract number 622/UN7.5.2/HK/2022.

### REFERENCES

- Agriflo. 2012. Itik Potensi Bisnis dan Kisah Sukses Praktisi. Jakarta (Indones): Penebar Swadaya.
- Ahmad S, Khaliq A, Pasha TN, Mehmoof S, Sohail Ahmad S, Khan AM, Hussain K. 2018. Influence of *Moringa oleifera* leaf meal used as phytogenic feed additive on the serum metabolites and egg bioactive compounds in commercial layers. *Brazilian J Poultry Sci.* 20:325-332. DOI:10.1590/1806-9061-2017-0606.
- Amir S, Ahmad T, Umer M, Rehman A, Hussain Z. 2014. Prevention and control of Newcastle disease. *IJAIR.* 3:454-460.
- Apriliyani F, Suthama N, Wahyuni HI. 2013. Rasio Heterofil Limfosit dan Bobot Relatif Bursa Fabricius Akibat Kombinasi Lama Pencahayaan dan Pemberian Porsi Ransum Berbeda Pada Ayam Broiler. *Anim Agric J.* 2:393-399.
- Bhakty ZW, Kencana GAY, Suartha IN. 2018. Titer antibodi ayam petelur pascavaksinasi *Avian Influenza* pada peternakan komersial di Desa Denbantas, Kecamatan Tabanan. *Indones Med Vet.* 7:123-131. DOI:10.19087/imv.2018.7.2.123.
- Dillasamola D, Aldi Y, Fakhri M, Diliarosta S, Biomechy OP. 2018. Immunomodulatory effect test from Moringa leaf extract (*Moringa oleifera* L.) with carbon clearance method in male White Mice. *Asian J Pharm Clin Res.* 11:241-245. DOI:10.22159/ajpcr.2018.v11i9.26703.
- Fidianny I, Kenapa I, Singgih M. 2021. Phytochemistry and pharmacology of Moringa tree: an overview. *Biointerface Res Appl Chem.* 11:10776-10789. DOI:10.33263/BRIAC113.1077610789.
- Hofmann T, Schmucker SS, Bessei W, Grashorn M, Stefanski V. 2020. Impact of housing environment on the immune system in chickens: a review. *Anim.* 10:1-26 DOI:10.3390/ani10071138.
- Kasiyati K, Djaelani MA, Sunarno S. 2021. Hematological Responses of pengging ducks fed Moringa (*Moringa oleifera*) leaf meal as feed additives. *J Vet.* 22:8-15. DOI:10.19087/jveteriner.2021.22.1.8.
- Kurnianto AB, Kencana GAY, Astawa INM. 2016. Respons antibodi sekunder terhadap penyakit tetelo pada ayam petelur pascavaksinasi ulangan dengan vaksin tetelo aktif. *J Vet.* 17:331-336. DOI:10.19087/jveteriner.2016.17.3.331.
- Li C, Dong Z, Zhang B, Huang Q, Liu G, Fu X. 2020. Structural characterization and immune enhancement activity of a novel polysaccharide from *Moringa oleifera* leaves. *Carbohydr Polym.* 234:115897.
- Lokapirnasari WP, Agustono B, Arif MAA, Maslachah L, Chandra EH, Yulianto AB. 2022. Effect of probiotic and *Moringa oleifera* extract on performance, carcass yield, and mortality of Peking duck. *Vet World.* 15:694-700. DOI:10.14202/vetworld.2022.694-700.
- Maggi-Capeyron MF, Cases J, Badia E, Cristol JP, Rauanet JM. 2002. A diet high in cholesterol and deficient in vitamin E induces lipid peroxidation but does not enhance antioxidant enzyme expression in rat liver. *J Nutr Biochem.* 13:296-301.
- Meel MS, Sharma T. 2021. Effect of feeding *Moringa oleifera* leaf meal as feed additive on the performance and carcass characteristics of broiler chicks. *Int J Curr Microbiol App Sci.* 10:40-46 DOI:10.20546/ijcmas.2021.1001.006.
- Miller PJ, Decanini EL, Afonso CL. 2010. Newcastle Disease: evolution of genotypes and the related diagnostic challenges, infection, genetics, and evolution. *Infect Gen.* 10:26-35.
- Novitasari A, Suardana IBK, Sampurna IP. 2018. Respon imun itik Bali pascavaksinasi Newcastle Disease. *Bul Vet Udayana.* 10:127. DOI:10.24843/bulvet.2018.v10.i02.p04.
- [OIE] Office International des Epizooties. 2021. Newcastle Disease (infection with Newcastle Disease virus). *Manual of diagnostic test and vaccines for terrestrial animals 2021.* p:10.
- Okoroafor ON, Ogunniran TM, Ikenna-ezeh NH. 2021. Effects of dietary supplementation of vitamins E and C on oxidative stress induced by a Nigerian velogenic strain of the Newcastle Disease virus (KUDU 113) in the brain and bursa of fabricius of broiler chickens. *14:2452-2461.*
- Phongpaichit S, Nikom J, Rungjindamai N, Sakayaroj J, Towatana NH, Rukachaisirikul V, Kirtikara K. 2007.

- Biological activities of extracts from endophytic fungi isolated from garcinia plants. *FEMS Immunol Med Microbiol.* 51:517-525. DOI:10.1111/j.1574-695X.2007.00331.x.
- Pratama L, Santosa PE, Siswanto. 2016. Pengaruh dosis vaksin Newcastle Disease inaktif pada itik betina terhadap jumlah sel darah putih dan titer antibodi. *J Ilmiah Peternak Terpadu.*4:211-216.
- Rahmayanti RP, Isroli. 2019. Pengaruh penambahan tepung daun kelor (*Moringa oleifera*) dan tepung bawang putih (*Allium sativum*) dalam pakan terhadap total leukosit dan diferensial leukosit ayam broiler. *Proceeding Seminar Nasional Fakultas Pertanian UNS.* p:138-144.
- Raji AA, Mohammed B, Oladele SB, Saidu L, Jibril AH, Cazaban G. 2017. Bursa body index as a visual indicator for the assessment of bursa of fabricius. *J Vet Med Anim Health.* 9:32-38. DOI:10.5897/JVMAH 2016.0456.
- Righi F, Pitino R, Manuelian CL, Simoni M, Quarantelli A, De Marchi M, Tsiplakou E. 2021. Plant feed additives as natural alternatives to the use of synthetic antioxidant vitamins on poultry performances, health, and oxidative status: a review of the literature in the last 20 years. *Antioxid.* 10. DOI:10.3390/antiox10050659.
- Rozi F, Rahmahani J, Purnama MTE, Hamid IS, Yudhana A, Praja RN. 2020. Seroprevalensi antibodi Newcastle Disease (ND) pada Itik di Desa Temuasri, Sempu, Banyuwangi. *J Med Vet.* 3:108-113.
- Sahin K, Sahin N, Onderci M, Gursu MF, Issi M. 2003. Vitamin C and E can alleviate negative effects of head stress in Japanese quails. *Food Agric Environ.* 1:244-249.
- Saputra A, Arfi F, Yulian M. 2020. Literature review: analisis fitokimia dan manfaat ekstrak daun kelor (*Moringa oleifera*). *Amina.* 2:114-119.
- Saputro BE, Sutrisna R, Santosa PE, Fathul F. 2016. Pengaruh ransum yang berbeda pada itik jantan terhadap jumlah leukosit dan diferensial leukosit. *J Ilmiah Peternak Terpadu.* 4:176-181.
- Soha A, Frejus O, Ohouko H. 2020. Immunomodulatory properties of *Moringa oleifera* in animal and human nutrition. *Pharmacogn Phytother.* 12:1-9. DOI:10.5897/JPP2019.0551.
- Purnomo D, Sugiharto, Isroli. 2015. Total leukosit dan diferensial leukosit darah ayam broiler akibat penggunaan tepung onggok fermentasi *Rhizopus oryzae* pada ransum. *J Ilmu-Ilmu Peternak.* 25:59-68. DOI:10.21776/ub.jiip.2015.025.03.08.
- Sulistiyanto B, Kismiati S, Utama CS. 2019. Tampilan produksi dan efek imunomodulasi ayam broiler yang diberi ransum berbasis wheat pollard terolah. *J Vet.* 20:352. DOI:10.19087/jveteriner.2019.20.3.352.
- Sun Q, Yang H, Yu J, Liang J, Xu X, Wang Z. 2022. Effect of dietary vitamin E on growth performance, immunity and antioxidant capacity in male Jiangnan White Goslings from 1 to 28 d of age. *Agric.* 12:1-9. DOI:10.3390/agriculture12010083.
- Susanty RNA, Chaerrudin A, Yudistirani SA. 2019. Antioksidan daun kelor. *J UMJ.* 21:1-7.
- Tabbu CR. 2000. Penyakit ayam dan penanggulangannya. Yogyakarta (Indones): Kanisius.
- Wbowo SE, Asmara W, Wibowo MH, Sutrisno B. 2013. Perbandingan tingkat proteksi program vaksinasi Newcastle Disease pada broiler. *JSV.* 31.
- Widada H. 2013. analisis kandungan vitamin E pada Buah *Borassus flabellifer* Linn. menggunakan high performance liquid chromatography (HPLC). *J. Kedokt Kesehatan Mutiara Medika.* 13:143-150.
- Widyaningsih PO, Sudira IW, Suardana IBK. 2020. Titer antibodi ayam kampung yang diberikan jamu daun ashitaba (*Angelica Keiskei*) menurun pascavaksinasi penyakit tetelo. *Indones Med Vet.* 9:446-455. DOI:10.19087/imv.2020.9.3.446.
- Winddi A, Purnama ES, Sri S. 2016. Pengaruh pemberian dosis vaksin AI (*Avian Influenza*) inaktif pada itik betina terhadap titer antibodi yang dihasilkan. *J Ilm Peternak Terpadu.* 4:140-142.
- Xiao S. 2012. Complete genom sequences of Newcastle Disease virus strain circulating in chickens populations of Indonesia. *J Virol.* 86:5969-5970.
- Yang SL, Yang RC, Zhou X, Yang SH, Luo LL, Zhu YC, Boonanuntan S. 2020. Effects of feeding diets with processed *Moringa oleifera* stem meal on growth and laying performance, and immunological and antioxidant activities in laying ducks. *Poult Sci.* DOI:10.1016%2Fj.psj.2020.04.002.
- Yuliani NS, Sakan GYI. 2018. Respon titer antibodi pada ayam broiler yang divaksinasi ND dan diberi herbal rempah. *Pertner.* 23:696-704.